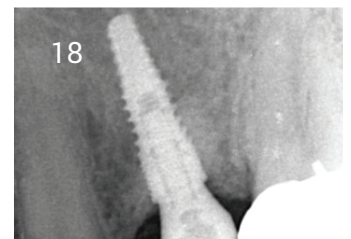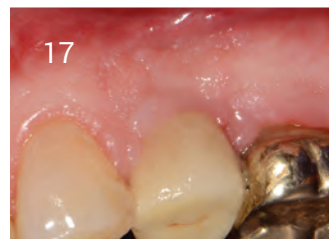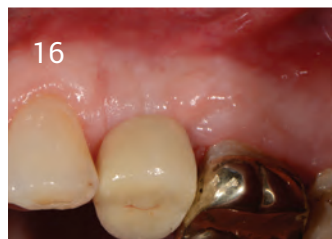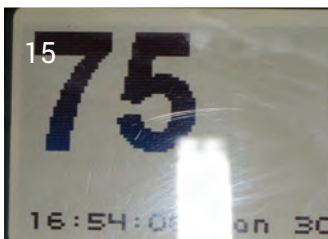
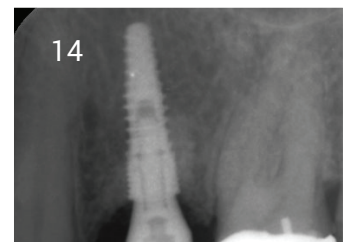
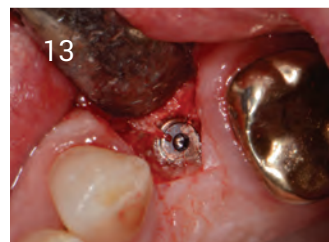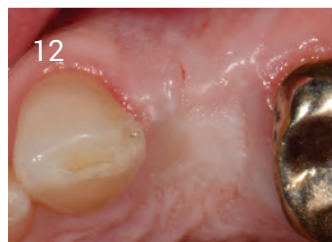
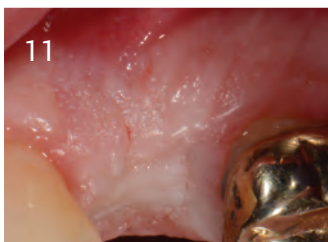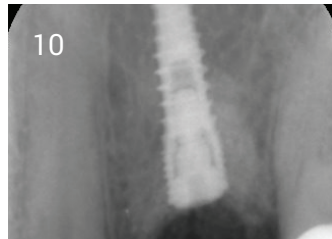
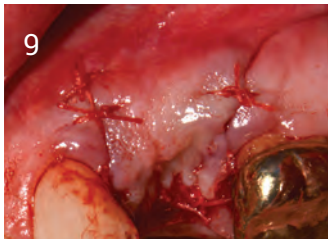
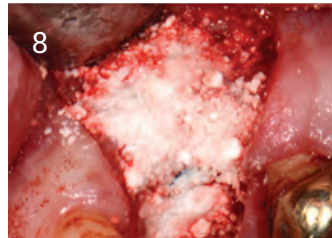
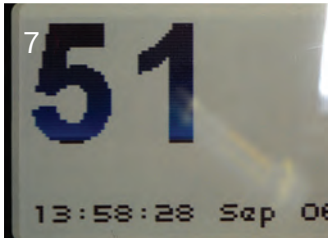
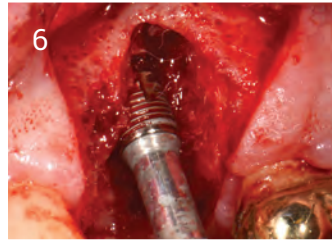
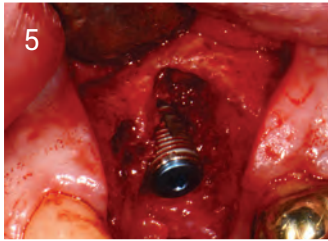
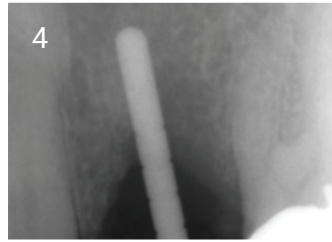
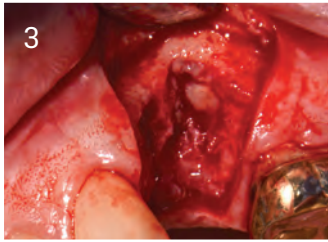


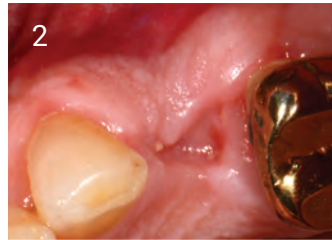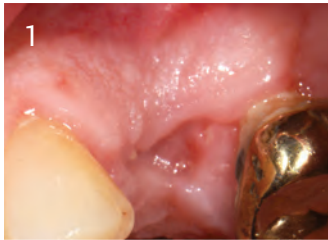## Upper Left 4 Case Study

1. 3 weeks post healing, bone loss shown
2. Profile loss
3. Flap raise to show bone loss
4. Pilot bur showing bone loss
5. Dio Implant placed
6. Osstell peg fitted
7. Reading at placement 51 ISQ
8. Grafted with Ethoss
9. Sutured closed
10. X-ray of grafted site
11. Healed site at 12 weeks
12. Healed site at 12 weeks
13. Raised flap to show new hard tissue
14. 12 weeks healed site loaded
15. Osstell now 75 ISQ showing integration
16. Loaded at 12 weeks
17. Loaded 2 years
18. Loaded 2 years

Case by Dr. Peter Fairbairn,  
Scarsdale Dental Aesthetic & Implant Clinic



A biphasic matrix for true bone regeneration.  
Built in membrane function, high graft stability.

**Regenamed Ltd**

8 Ryefield Court, Silsden, BD20 0DL  
www.ethoss.co • info@ethoss.co