

The body wants to heal, let's work with it.

Multiple Tooth Bridge Case Study

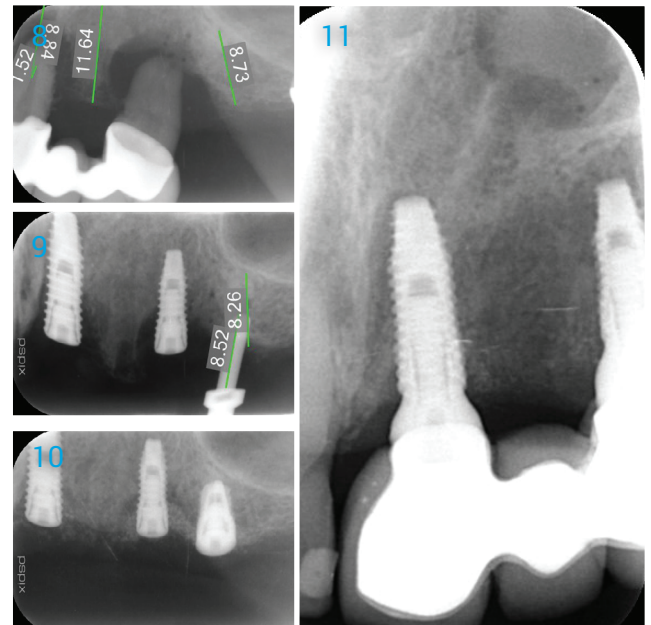
1. Flap raised to show the bone loss.
2. Implant Placed into optimal position with defects.
3. Grafted with EthOss and allowed to "set".
4. Ridge after 12 weeks healing.
5. Flap raised to show new hard tissue covering Implant heads.
6. Osstell readings taken (Mid 70's all three)
7. 1 year loaded showing long term tissue stability.

Radiographs

8. Periodontal disease of bridge.
9. Placing Implants showing bone defects.
10. Grafted after 1 week.
11. 1 year loaded showing stable hard tissue.

Case by Dr. Peter Fairbairn,

Scarsdale Dental Aesthetic & Implant Clinic



A biphasic matrix for true bone regeneration.
Built in membrane function, high graft stability.

Regenamed Ltd

8 Ryefield Court, Silsden, BD20 0DL
www.ethoss.co • info@ethoss.co