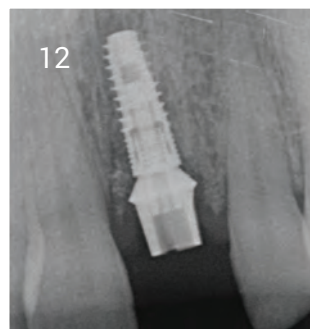
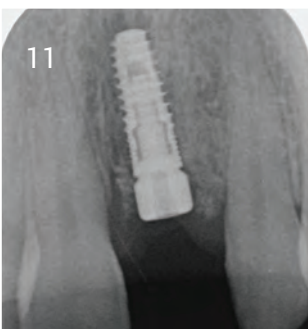
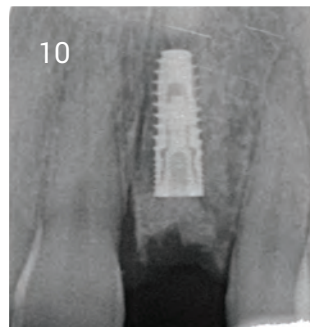
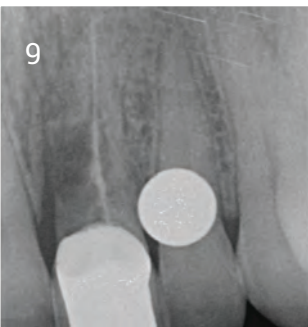
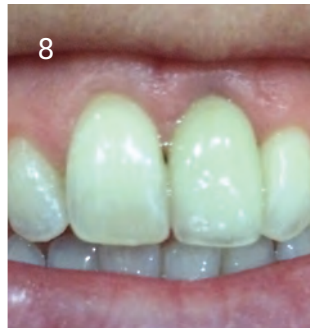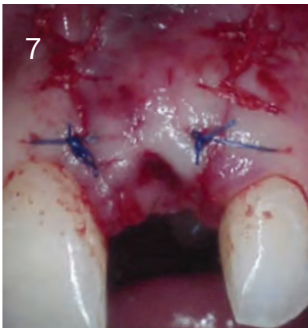
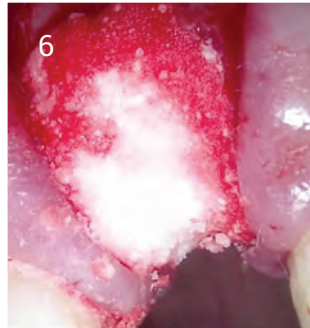
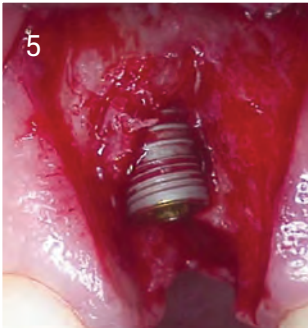
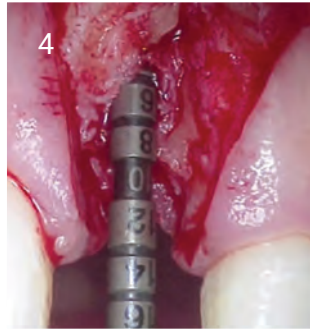
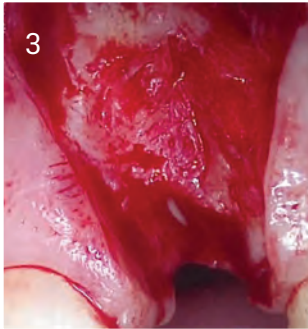

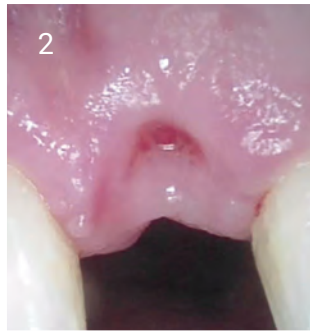
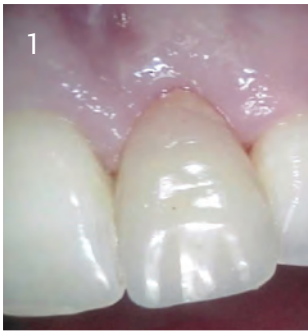## Anterior Case Study

1. Denture pre-surgery.
2. Post Extraction Site.
3. Flap opened.
4. Depth of socket measured.
5. Implant placed.
6. ethoss® graft placed at site.
7. Graft sutured over with good soft tissue closure.
8. Aesthetic result at review (16 weeks).

## Radiographs

9. Radiograph pre-surgery showing extreme bone loss.
10. Radiograph post graft and implant placement.
11. Implant with healing abutment and vertical bone growth.
12. Implant with abutment showing even more vertical bone growth.



A biphasic matrix for true bone regeneration.  
Built in membrane function, high graft stability.

**Ethoss Regeneration Ltd**

8 Ryefield Court, Silsden, BD20 0DL, UK

www.ethoss.co • info@ethoss.co